

CASE REPORT

Echocardiographic Diagnosis of Ruptured Sinus of Valsalva with Congenital VSD and AR

Sitaram Gupta, MBBS, MD, PGDCC, Ram Chitlangia, MBBS, MD, DM, Deepak Garg, MBBS, PGDCC, Jaipur, India

ABSTRACT

Rupture of sinus of valsalva (RSOV) is rare cardiac lesion. It is a form of left to right shunt due to rupture of aortic sinus into Right Ventricle (RV) or Right Atrium (RA). This may be isolated or associated with other cardiac lesions such as ventricular septal defect (VSD), aortic regurgitation, bicuspid aortic valve and coarctation. RCC prolapse with rupture of RSOV is also frequently noticed in cases of doubly committed VSDs.

Echocardiography is a powerful diagnostic tool for detection of the lesion. We present a case of RSOV associated with subaortic VSD and AR, in a 27-year-old man. The diagnosis was made by echocardiography and confirmed at operation. (J Clin Prev Cardiol. 2015;4(1):24-6)

Key words: Rupture of sinus of valsalva (RSOV), Ventricular septal defect (VSD), Aortic Regurgitation (AR), Right coronary cusp (RCC).

Introduction

Rupture of Sinus of Valsalva is rare but potentially life threatening clinical entity which requires immediate recognition and intervention. The presentation may range from an asymptomatic continuous murmur to acute cardiogenic shock and death. RSOV is either isolated lesion or associated with ventricular septal defect (VSD). Defect in this part of the ventricular septum involve the infundibular septum and thus lie underneath both semilunar valves. Lack of supporting tissue for the aortic annulus precipitate prolapse of aortic cusp into RV and aneurysm of sinus of Valsalva. This aneurysm has potential to get ruptured (1). Most of the times, the VSDs associated with RCC prolapse with RSOV are doubly committed VSDs.

Echocardiography has become the definitive investigation tool not only to define and diagnose the lesion but also to quantify its severity. Thus it plays a critical role in management of the patient (2).

Case Report

A 27-year-old male with a history of childhood murmur was a diagnosed case of VSD. This person was referred

From: Department of Cardiology, Narayana Multispeciality Hospital, Jaipur, Rajasthan (S.G., R.C., D.G.)

Corresponding Author: Dr Sitaram Gupta,
Department of Cardiology, Narayana Multispeciality Hospital,
Sector-28, Kumbha Marg, Pratap Nagar, Sanganer, Jaipur,
Rajasthan -302033

Email: sitaram_gpt@yahoo.com

to our institution for progressive heart failure symptoms with pricking chest pain especially on bending forward for last one year. On physical examination he had BP of 120/50 mmHg and pulse was 80/min. On cardiac examination systolic thrill and continuous murmur over the left sternal border was detected. Electrocardiogram was normal. A chest radiograph demonstrated a slightly enlarged cardiac silhouette and increased pulmonary blood flow. Transthoracic echocardiography demonstrated normal LV systolic functions. There was sub aortic VSD of around 7 mm below the aortic valve and discontinuity in the wall of right coronary sinus. Color flow Doppler revealed a continuous turbulent flow between right sinus of Valsalva and the right ventricle (above the aortic valve). Prolapse of RCC (which is restricting the VSD) into RV with mild eccentric AR was also noticed. The diagnosis was confirmed in operating room and patient underwent successful patch closure of the VSD along with repair of the RSOV. The dyspnea improved postoperatively and the patient is doing fine on follow-up

Discussion

Ruptured sinus of Valsalva is an uncommon condition with protean clinical manifestation. Rupture is often with an abrupt onset and the presentation may range from an asymptomatic murmur to acute cardiogenic shock and death.

A retrospective analysis of RSOV cases reported in Singapore General Hospital revealed that half of the

cases were having VSD and 1/3rd cases were associated with AR. Rupture of right coronary cusps was much more common (83%) than non-coronary cusp (17%) and left coronary cusp (0%). Most of the RCC ruptures were directed into the RV and all of the NCC ruptures were into the RA (3).

Males are more affected than females (3:1 ratio), and the prevalence is higher in the Eastern than in the Western population (4).

Transthoracic echocardiography is the main diagnostic tool for the identification of the RSOV, while transesophageal imaging may further help the diagnosis and in surgical correction of the lesion, especially when VSD is also present. Echocardiography can also provide important information necessary for the differential diagnosis from other disorders which cause continuous murmur, such as patent ductus arteriosus, aorticopulmonary window, coronary fistula, as well as co-existing VSD and aortic valve regurgitation (5).

In conclusion, RSOV is a rare condition with a varied presentation that sometimes can be fatal if not diagnosed quickly. Right coronary sinus of Valsalva to right ventricle ruptures are the commonest type of RSOV and there is an association with VSD, aortic regurgitation and infective endocarditis. Trans-thoracic echocardiography is the reliable diagnostic tool for the identification of the aneurysms of sinus of Valsalva, while multiplane transesophageal imaging may further help in the diagnosis and intraoperative surgical correction of the lesion, especially when VSD is also present.

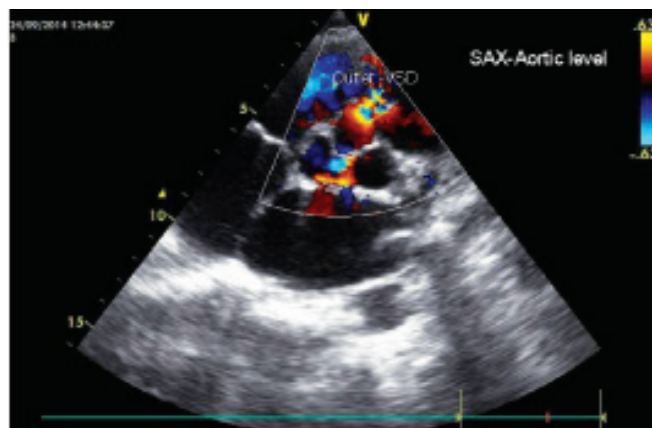


Image 2. Parasternal short axis view - Illustrating the flow across the outlet VSD

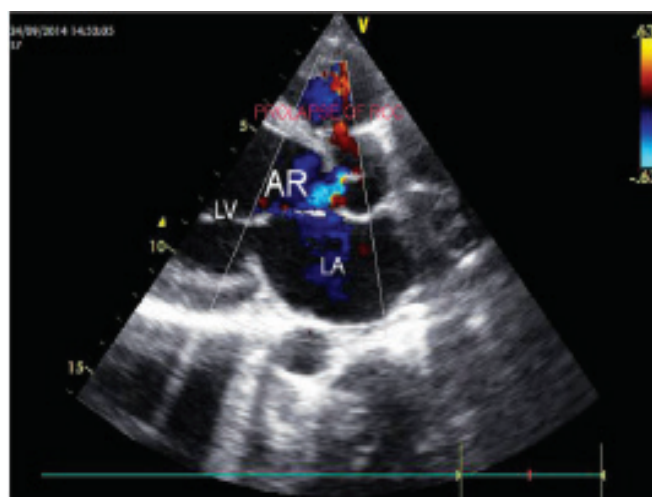

Image 3. Parasternal long axis view - showing the mild AR with prolapsed of RCC through VSD

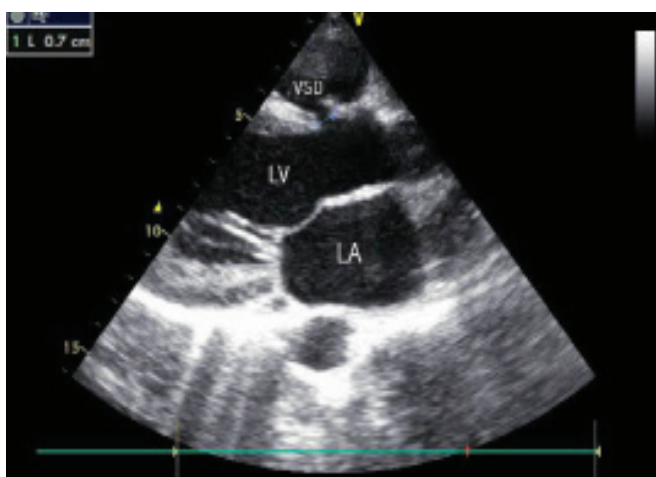

Image 1. Parasternal long axis view- Illustrating the ventricular septal defect of 7mm

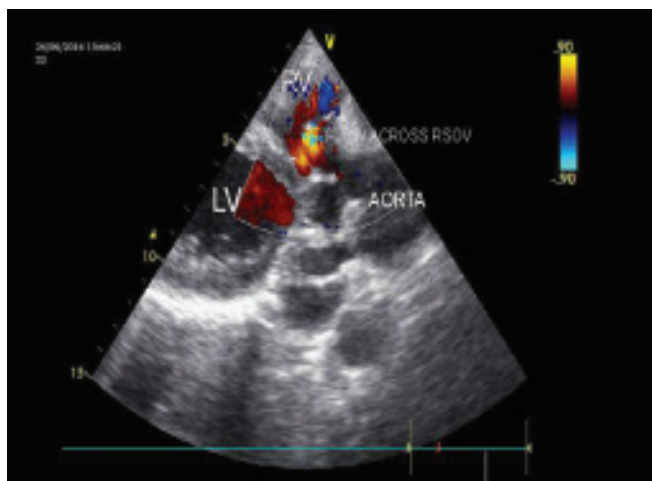


Image 4. Parasternal long axis view – showing flow across RSOV in to RV

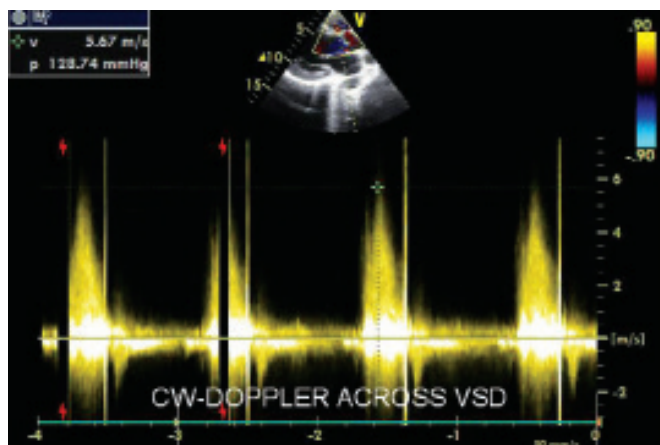


Image 5. Continuous wave Doppler to measure the pressure gradient across VSD restricted by prolapsed of RCC

References

1. AR Moarref, S Afifi, M Jannati, GR Rezaian. Ruptured sinus of valsalva aneurysm initially misdiagnosed as ventricular septal defect by echocardiography. Iranian Cardiovascular Research Journal 2009;3:123-5.
2. Grosz C, Pais R, Poanta L.. Rupture sinus of Valsalva in a patient with dextrocardia. Case report. Med Ultrason. 2011;13:323-5.
3. Shah RP, Ding ZP, Ng AS, Quek SS.. A ten –year review of ruptured sinus of valsalva: Clinico-Pathological and ECHO-Doppler Features. Singapore Med J 2001;42:473-6.
4. Tipoo Sultan FA, Basir N, Fatimi S. Aneurysm of Sinus of Valsalva. J Coll Physicians Surg Pak. 2011;21:173-5.
5. Lakoumentas JA, Bonou MS, Brili S, Theocharis CS, Benroubis AD, Perpinia AS, Harbis PK. Ruptured Aneurysm of the Right Sinus of Valsalva Into the Right Ventricle. Hellenic J Cardiol. 2002;43:242-5.